# Clostridium septicum sepsis with Intra-abdominal Gas Gangrene in the setting of GI Malignancy

*Kevin S. Puri, OMS-II, 2d Lt, USAF; Anirudh Rai, MD; Anthony J. LaPorta, MD, FACS, FACOS, Col (ret), USA; Tuan Hoang, MD, FACS, CAPT, USN*

## INTRODUCTION

*Clostridium septicum* is a normal commensal of the human intestinal tract and rarely the source of opportunistic infection. We explore the case of a patient with *C. septicum* sepsis with lethal intra-abdominal infection associated with GI malignancy. Although its definitive link to carcinoma has not been identified, this species is, nonetheless, associated with worsening malignancy. Quick and accurate identification is imperative for beginning aggressive antibiotic therapy.

## CASE PRESENTATION

HPI
A 58 y.o. female with a past medical history of metastatic colon cancer presents to the hospital for worsening diffuse abdominal pain, nausea, and vomiting. + Fever and chills. Over the past year, she had gradual worsening RLQ abdominal pain, weight loss, vomiting, and decrease in appetite.

PMH: GERD, HTN, and migraines
Family History: HTN and no hx of colon cancer
Physical Exam: T 101, HR 100, BP 126/96, RR 22, 95% on 1L NC. Abdomen: soft, diffuse tenderness, rebound
Labs: WBC 19.7, CR 0.83. Tot bilirubin 3.5, AST 68, ALT 64, ALP 1397, CRP 118. UA + trace bacteria.
Imaging: Abdominal and pelvic CT with contrast – incremental increase in size of gas-forming and non-gas forming hepatic lesions. The appearance of gas-forming abscesses is seen with lobulated zone of coagulated necrosis surrounding it. Evidence of intra-abdominal gas.

## RESULTS

The patient was admitted and taken to the OR for exploratory laparotomy for peritonitis secondary to perforated viscus. Laparotomy revealed thickened, adhesive bowel throughout the suprapubic region, pelvis, and RLQ. Significant amount of turbid ascitic fluid was noted. Multiple large necrotic masses were noted on the omentum and multiple small studding were noted in the mesenteries. Omentectomy, with all palpable masses, bilateral oophorectomy, and the adhered ruptured abscesses. The abdomen was washed with 4L of sterile water, after which two JP drains were placed in the pelvis and RLQ. Ileostomy/split fistula of the ascending colon in the RLQ was created. Blood and turbid ascitic fluid culture both revealed *C. septicum.* The patient continued aggressive Metronidazole and Piperacillin/Tazobactam therapy postoperatively. The patient recovered from the surgery and was discharged home with guidance from Hospice, where she spent her last days with family and friends.

## IMAGING

Figure 1. Coronal view CT Abdomen and pelvis with contrast with evidence of intra-abdominal gas and presence of hepatic abscesses

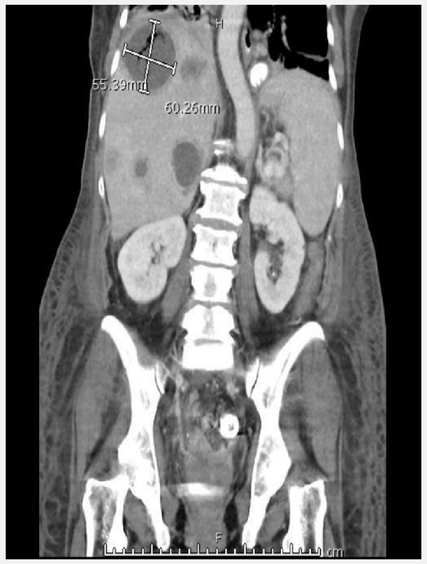


Figure 2: Coronal view of CT Abdomen pelvis with multiple intrahepatic abscesses

Figure 3. Coronal view of CT Abdomen pelvis with evidence of intrahepatic abscesses with suspected fistula to the stomach

Figure 4. Median view of CT abdomen and pelvis with intrahepatic abscess with possible fistula to the stomach

## DISCUSSION

*Clostridium septicum* is an opportunistic infectious agent that becomes virulent in the backdrop of defective host immunity and is strongly associated with colorectal malignancy. Pathogenesis of the bacterium involves spreading infection through the fascial planes around an area of injury linked to its swarming motility and virulence factors. Swarming involves the bacterium differentiating into giant hyperflagellated swarm cells which purvey the bacteria its capacity to translocate across mucosal surfaces. Any loss of intestinal mucosal integrity secondary to malignancy disease, including IBD like Chron's disease, places patients at risk. Furthermore, immunosuppressed or immunocompromised states further add to the bacterium's invasiveness.

Most important of the virulence factors includes the alpha toxin. These exotoxins hydrolyze cellular membranes, causing tissue necrosis by inducing occlusive microvascular thrombosis, which leads to pore formation. This leads to eventual myonecrosis. Another factor that contributes to patient mortality is the fact that *C. septicum* does not require a strict anaerobic environment, unlike *C. difficile, C. botulinum, and C. perfringens.*

This case highlighted the bacteria's ability to be locally invasive (caused gas gangrene) and yield subsequent systemic bacteremia and septicemia by hematogenous spread. The most likely etiology is translocation of the bacteria through different layers of the gastrointestinal tract. This etiology as a cause of *C. septicum* infection in the setting of GI malignancy is rare in the literature. Early identification of *C. septicum* infections is critical for prompt and aggressive antibiotic therapy to be initiated.

## REFERENCES

1. Chew SS, Lubowski DZ. Clostridium septicum and malignancy. ANZ J Surg. 2001Nov;71(11):647-9. doi: 10.1046/j.1445-1433.2001.02231.x. PMID: 11736823.
2. Nanjappa S, Shah S, Pabbathi S. Clostridium septicum Gas Gangrene in Colon Cancer: Importance of Early Diagnosis. *Case Rep Infect Dis*. 2015;2015:694247. doi:10.1155/2015/694247
3. Pelletier JP, Plumbley JA, Rouse EA, Cina SJ. The role of Clostridium septicum inparaneoplastic sepsis. Arch Pathol Lab Med. 2000 Mar;124(3):353-6. doi: 10.1043/0003-9985(2000)124<0353:TROCSI>2.0.CO;2. PMID: 10705386.
4. Sidhu JS, Mandal A, Virk J, Gayam V. Early Detection of Colon Cancer Following Incidental Finding of Clostridium septicum Bacteremia. *J Investig Med High Impact Case Rep*. 2019;7:2324709619832050. doi:10.1177/2324709619832050
5. Wells, C. L., & Wilkins, T. D. (n.d.). Medical microbiology. 4th edition. In *MedicalMicrobiology. 4th edition*. University of Texas Medical Branch at Galveston.
6. Wentling GK, Metzger PP, Dozois EJ, Chua HK, Krishna M. Unusual bacterial infectionsand colorectal carcinoma--Streptococcus bovis and Clostridium septicum: report of threecases. Dis Colon Rectum. 2006 Aug;49(8):1223-7. doi: 10.1007/s10350-006-0576-4. PMID: 16845563.
7. Claridge JA, Banerjee A, Kelly KB, Leukhardt WH, Carter JW, Haridas M, Malangoni MA. Bacterial species-specific hospital mortality rate for intra-abdominal infections. Surg Infect (Larchmt). 2014 Jun;15(3):194-9. doi: 10.1089/sur.2011.039. Epub 2014 May 6. PMID: 24801801; PMCID: PMC4063368.
8. (8)Kennedy CL, Lyras D, Cordner LM, et al. Pore-forming activity of alpha-toxin is essential for clostridium septicum-mediated myonecrosis. *Infect Immun*. 2009;77(3):943-951. doi:10.1128/IAI.01267-08
9. (9)Aldape MJ, Bayer CR, Rice SN, Bryant AE, Stevens DL. Comparative efficacy of antibiotics in treating experimental Clostridium septicum infection. Int J Antimicrob Agents. 2018;52(4):469-473. doi:10.1016/j.ijantimicag.2018.07.009
10. (10) Macfarlane S, Hopkins MJ, Macfarlane GT. Toxin synthesis and mucin breakdown are related to swarming phenomenon in Clostridium septicum. *Infect Immun*. 2001;69(2):1120-1126. doi:10.1128/IAI.69.2.1120-1126.2001
11. Panikkath, R., Konala, V., Panikkath, D., Umyarova, E., & Hardwicke, F. (2014). Fatal Clostridium septicum infection in a patient with a hematological malignancy. *Proceedings (Baylor University. Medical Center)*, *27*(2), 111–112.
12. Khan, A. A., & Davenport, K. (2006). A reminder of the association between Clostridium septicum and colonic adenocarcinoma. *International seminars in surgical oncology : ISSO*, *3*, 12.